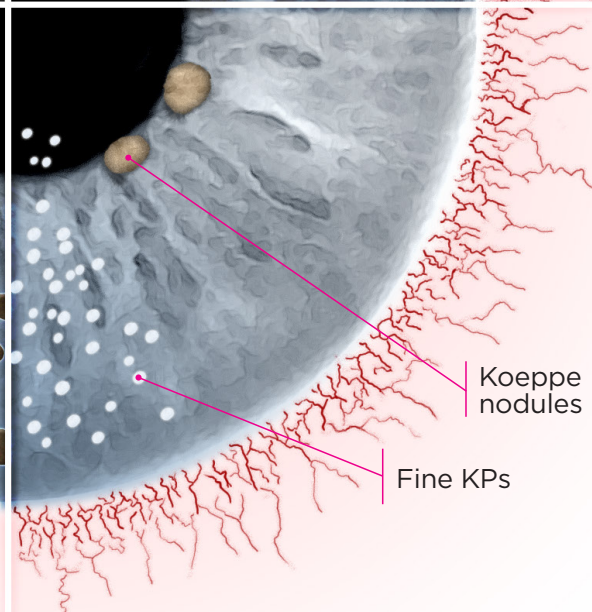
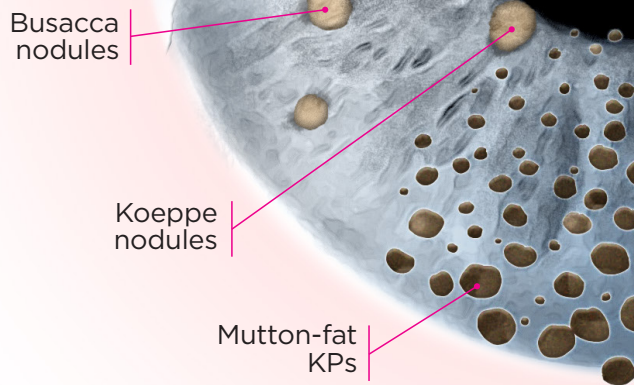
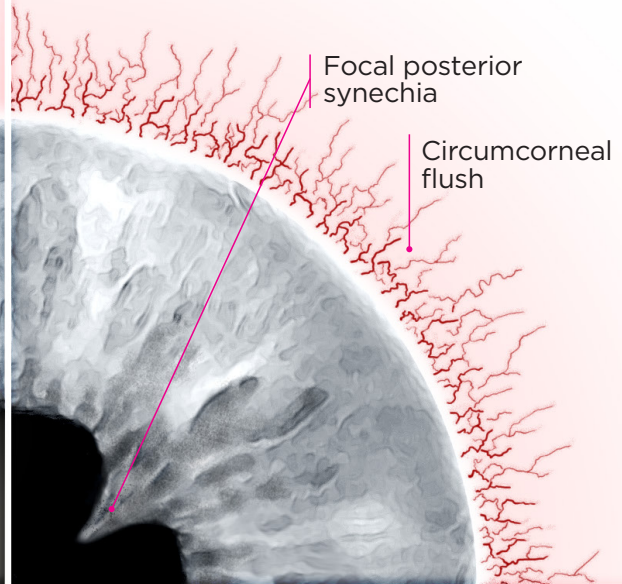
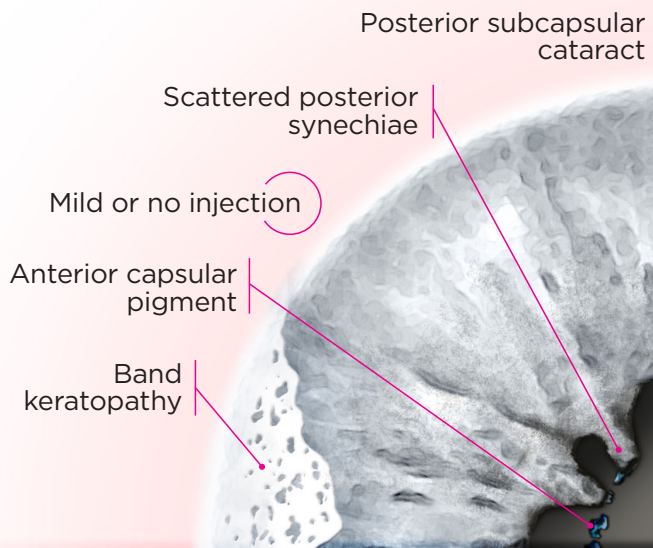


Clinical Signs of Anterior Uveitis

CHRONIC

ACUTE



GRANULOMATOUS

NON-GRANULOMATOUS